

COMPARATIVE EVALUATION OF INTERNAL FIXATION OF TROCHANTERIC FRACTURES OF FEMUR WITH DYNAMIC HIP SCREW (DHS) AND DYNAMIC CONDYLAR SCREW (DCS) FIXATION

Sandeep Kumar¹, Kumari Rashmi², Vir Abhimanyu Pandit³, Kumar Anshuman⁴

¹Senior Resident, Department of Orthopedics, Narayan Medical College & Hospital, Jamuhar, Rohtas, Bihar, India

²Tutor, Department of Pathology, JLNMC, Bhagalpur, Bihar, India

³Associate Professor, Department of Surgery, Narayan Medical College & Hospital, Jamuhar, Rohtas, Bihar, India.

⁴Professor & Head of Department, Department of Orthopedics, Narayan Medical College & Hospital, Jamuhar, Rohtas, Bihar, India

Received : 05/02/2024
Received in revised form : 30/03/2024
Accepted : 14/04/2024

Keywords:

Intertrochanteric fractures, Dynamic Condylar Screw (DCS), Dynamic Hip Screw (DHS).

Corresponding Author:

Dr. Kumar Anshuman,

Email: kumaranshuman@hotmail.com

DOI: 10.47009/jamp.2024.6.5.162

Source of Support: Nil,

Conflict of Interest: None declared

Int J Acad Med Pharm
2024; 6 (5); 847-850



Abstract

Background: The goal of this study was to determine the best implant among the dynamic hip screw and dynamic Condylar screws for treating unstable intertrochanteric fractures, as well as the benefits and drawbacks of each implant. **Materials and Methods:** This cross-sectional interventional study was conducted in the Department of Orthopedics, Narayan Medical College & Hospital, Jamuhar, Rohtas, Bihar. Study period was September 2019 to August 2020. Institutional ethical approval was obtained for the study. Written consent was obtained from all the participants of the study. **Result:** A total of n=50 cases of unstable intertrochanteric fractures were included in the study. The youngest case was a 34-year-old male and the oldest case was 75 years old male. The most common age group was in the range of 61 – 80 years, with a mean age of 61.6 ± 6.4 years. In the DHS cases, n=30 (60%) were females and n=20(40%) were males. In DCS group n=33 (66%) were females and n=17(36%) were males. **Conclusion:** DCS may be considered a better implant than DHS in treating the unstable intertrochanteric fractures.

INTRODUCTION

All hip fractures occur at a rate of about 80 per 100,000 people. 45 percent of all hip fractures are intertrochanteric fractures.^[1] They are three to four times more common in osteoporotic women, with the most common mechanism of injury being a minor fall.^[2] The etiology of unstable intertrochanteric fractures in the younger age where they are more common is usually a high-energy trauma, such as a car collision. Intertrochanteric fractures are becoming more common as the number of senior persons with osteoporosis grows, as does the number of road traffic incidents. In the past, these fractures received less attention because they occurred through the cancellous bone, which has a great blood supply, and they healed without any active therapy. Conservative therapy, on the other hand, frequently resulted in malunion with varus and external rotation deformity, resulting in a short limb gait and a high death rate due to the co morbidities of recumbence and immobility.^[3] The goal of intertrochanteric fracture treatment is to return the patient to his or her pre-injury state as soon as possible. Internal fixation

of these fractures was used to improve patient comfort, ease nursing care, reduce hospitalization, and lessen problems associated with extended decubency periods. Malunion and varus angulations are prevalent if left untreated or treated poorly in unstable intertrochanteric fractures, resulting in significant morbidity. Because of the demands on the patient, nursing staff, and the length of hospitalization, conservative treatment of such fractures is no longer an option. Dynamic hip screw (DHS) fixation is routinely used to treat stable intertrochanteric fractures, with failure rates of less than 2%. The treatment of unstable intertrochanteric fractures is more debatable. Unstable intertrochanteric fractures treated with DHS have a much greater failure risk, ranging from 4% to 15%.^[4] Intramedullary devices, extramedullary devices, and hemiarthroplasty are some of the alternative therapeutic options for unstable intertrochanteric fractures. Despite numerous approaches, there has yet to be a gold-standard treatment for unstable fractures. Randomized clinical trials comparing the outcomes of Intramedullary versus extramedullary fixation or prosthetic replacement procedures for

unstable trochanteric fractures are inconclusive. The majority of comparative research concentrates on the treatment of stable trochanteric fractures. The goal of this study was to determine the best implant among the dynamic hip screw and dynamic Condylar screws for treating unstable intertrochanteric fractures, as well as the benefits and drawbacks of each implant.

MATERIALS AND METHODS

This cross-sectional interventional study was conducted in the Department of Orthopedics, Narayan Medical College & Hospital, Jamuhar, Rohtas, Bihar. Study period was September 2019 to August 2020. Institutional ethical approval was obtained for the study. Written consent was obtained from all the participants of the study after explaining the nature of the study and possible outcomes and complications.

Inclusion Criteria

- Age group 20 years to 80 years
- Both sexes

Exclusion Criteria

- Age less than 20yrs (before physal closure)
- Stable intertrochanteric fractures
- Open (compound) hip fractures
- Patients having associated shaft fracture
- Patients unfit for anesthesia and major surgical intervention

Material and Method

The present study consists of n=50 adult patients with unstable intertrochanteric fractures, among these n=25 cases were treated with Dynamic Hip Screw and other n=25 cases are treated with Dynamic Condylar Screw. The patients were evaluated as per the history, and mode of injury. Necessary radiological investigations and hematology profile was done upon admission. Type of surgery and details were noted. On arrival, all the patients were hemodynamically stabilized following which they were subjected to radiographic evaluation with the following x-rays:

- X-ray Pelvis with both Hips AP view
- AP view of the involved proximal femur with Traction and Internal rotation
- AP and Lateral views of the involved femur with the knee joint.

Other following investigations were done routinely on all the patients preoperatively including Hb%, total leucocytes count, differential count, blood grouping, cross matching, fasting blood sugar, blood urea, serum creatinine, serum electrolytes, Urine albumin, sugar, and microscopic examination. The fractures were classified based on the radiographs taken and management planned. The implants were chosen after taking into consideration the individual fracture morphology. The immediate post-operative x-rays were evaluated. Post-operative care: Patients were kept nil per orally for 4 to 6 hours post-operatively Intravenous fluid is given as needed. IV antibiotic is given for 3 days. The oral antibiotic

continued for 10 days. Analgesic and tranquilizers were given according to the need of the patient. The operated lower limb is immobilized & kept elevated. A check x-ray was taken to study the alignment of the fracture fragment. Reduction in both AP-Internal rotation & the lateral view was checked and Neck-Shaft angle was noted. The wound was inspected on the 2nd and 6th postoperative days. Suture removal was done on the 10th postoperative day depending on the condition of the wound. The follow-up was carried out at 6 weeks, 3 months, 6 months, and some cases. 1 year. The results were evaluated using "Modified Harris Hip Score Rating". [5] Maximum points are possible 100 at the end of six months postoperative period.

RESULTS

A total of n=50 cases of unstable intertrochanteric fractures were included in the study. Randomly allotted into two groups Dynamic Hip Screw (DHS) and Dynamic Condylar Screw (DCS). The youngest case was a 34-year-old male and the oldest case was 75 years old male. The most common age group was in the range of 61 – 80 years, with a mean age of 61.6 ± 6.4 years. In the DHS cases, n=30 (60%) were females and n=20(40%) were males. In DCS group n=33 (66%) were females and n=17(36%) were males.

Based on the lateralization of injuries. In DHS cases n=12(48%) cases were with Intertrochanteric fractures to the left side and n=13(52%) were right side Intertrochanteric fractures. Similarly, for the DCS group out of n=25 cases, n=16(64%) cases were Intertrochanteric fractures, and n=9(36%) were right side Intertrochanteric fractures. The mode of Intertrochanteric fractures revealed trivial falls as the most common reason for the fractures depicted in [Figure 1].

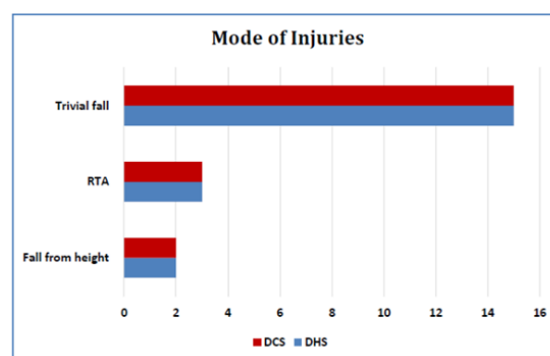


Figure 1: Showing the mode of injuries and their distribution in both groups

The involvement of sides in both groups was not statistically significant. The pre-injury walking ability of patients was classified as per grades described by Sahlstrand were recorded in both the groups. Fischer's exact test p values were 0.76 hence Pre-injury walking ability was similar in both the groups.

The mean duration of surgery for Dynamic Condylar screw was 77.4 ± 12.21 minutes. For Dynamic hip screw, the mean duration of surgery was 75.2 ± 4.6 minutes. The durations compared to DCS which may be due to extended proximal exposure in DCS cases. Dynamic hip screw fixation required less fluoroscopic time as compared to dynamic Condylar screws. This may be due to the application of an additional cancellous screw in the proximal fragment in DCS fixation. The mean duration of fluoroscopy time in DHS cases was 58.05 ± 5.3 minutes and for DCS the mean duration of fluoroscopy was 67.35 ± 3.53 minutes. The DHS fixation required less

fluoroscopic time as compared to the dynamic Condylar screw which could be due to the application of an additional cancellous screwing the proximal fragments in DCS fixations. The estimation of blood loss during the surgery found in DHS cases $n=18(90\%)$ had blood loss between 200 – 300 ml and between 300 – 400 ml in $n=3(12\%)$ cases and none of the cases was with > 400 ml blood loss. Similarly, in the DCS cases, $n=18(71\%)$ had blood loss of 200 – 300 ml and $n=5(20\%)$ had blood loss of 300 – 400 ml and > 400 ml blood loss was seen in $n=3(12\%)$ cases.

Table 1: Age-wise distribution of cases included in the study.

Age in years	Methods of Fixation					
	DHS	Percentage	DCS	Percentage	Total	Percentage
21- 40	5	20.00	5	20.00	10	20.00
41- 60	7	28.00	6	24.00	13	26.00
61- 80	13	52.00	14	56.00	27	54.00
Total	25	100	25	100	50	100

DISCUSSION

The aim of management in cases of unstable intertrochanteric fractures is to achieve early mobilization, rapid rehabilitation, and quick return of individuals to pre-morbid home and work environment as a functionally and psychologically independent unit. The Dynamic Hip Screw (DHS) is most commonly used and remains the Gold Standard for Stable intertrochanteric fractures. The Dynamic Condylar Screw (DCS) has traditionally been used in the treatment of unstable proximal femoral fractures, especially those with a reverse obliquity pattern or extension into the lateral wall. However, various studies using this implant have yielded contradictory results. According to the study by I. Saarenpää et al,^[7] Sliding Hip Screws used in the treatment of Unstable trochanteric fractures have a very high failure rate with a reoperation rate of 8.2% which is unacceptable in the present-day scenario. Haidukewych et al,^[8] noted that the Dynamic Condylar Screw performed significantly better than the Dynamic Hip Screw in their series of patients with a reverse oblique type of unstable proximal femoral fractures. The idea of controlled collapse rests on the principle of the collapsing forces being perpendicular to the fracture line. A device that traverses in alignment with these Compressing forces does excellently. The DHS, therefore, is an ideal implant for 3 AO 1 and some 3 AO 2 fractures. In the present study, we found the age of the patient ranged from 35 to 85 years with an average of 65.2 years. In the case of Dynamic hip Screw fixation, it was 64.2 years and in cases of the dynamic Condylar screw, it was 68.2 years. In a similar study SPS Gill et al,^[9] found the mean age of the DHS group to be 59.62 ± 15.61 years and the PFN group to be 62.81 ± 13.92 years. In our study, there were 20 males and 30 females showing female preponderance. E Dahl,^[10] in his study 60% of patients were females, explained by the fact that

female is more prone to osteoporosis after menopause. The duration of surgery in the current study in the DCS group ranged from 75 minutes to 100 minutes with a mean of 82.85 minutes. The duration of surgery in the DHS group ranged from 60 minutes to 90 minutes with a mean of 75.2 minutes. Karl Lunsjö et al,^[4] in a similar study also found that the surgical times were higher in the DCS group in their series. The median operating time for the DCS group was 70 min and in the DHS group was 45 mins. The overall average blood loss in this study was 273.5 ml which is comparable with the mean blood loss of 282ml in the study conducted by Bellabarba et al,^[11] The less blood loss was seen in patients undergoing DHS fixation with 90% having blood loss under 300ml and in DCS group 70% cases had less than 300ml blood loss. The mean modified Harris hip score in the present study was 81.68 and for the DHS group it was 83.2 and for DCS it was 80.15. Overall, 7 patients (17.5%) had Excellent, 19 patients (47.5%) had Good 10 patients (25%) had Fair, and another 4(10%) patients had poor scores according to the Modified Harris Hip Scoring system. AK Rudramuni et al,^[12] in a similar study found the mean Harris hip score was 85.02. The mean Harris hip score was 85.02 (PFN – 88.25, DHS – 83, PFLCP – 86.25, DCS – 82). In this study, the overall mean time for radiological fracture union was 17.55 weeks. The mean time of union in the DHS group was around 17.4 weeks which was less compared to the DCS group i.e around 18 wks. This may be due to the controlled compression at the fracture site with DHS implant and in this study, most of the A3 groups' fractures were fixed with DCS and the patient allowed delayed weight-bearing due to the risk of implant breakage. A Singh et al,^[13] in their study of management of intertrochanteric fractures found satisfactory fixation was achieved in 93.3% of the DCS group and 92% of the DHS group. Union was

seen at 12 weeks and 16 weeks depending on the quality of reduction and fixation.^[14]

CONCLUSION

Within the limitation of our study, we found DCS performed better than DHS in terms of overall functional outcome, less incidence of post-operative shortening, varus collapse screw back-outs, and almost similar rates of fracture union. Hence DCS may be considered a better implant than DHS in treating the unstable intertrochanteric fractures.

REFERENCES

1. JD Zuckerman: Hip fracture. *N Engl J Med* 1996; 334:1519-1523.
2. Kaufer H. Mechanics of the Treatment of Hip Injuries. *Clin Orthop*. 1980; 146:53-61.
3. Ly TV, Swiontkowski MF. Management of femoral neck fractures in young adults. *Indian J Orthop*. 2008;42(1):3-12.
4. Lunsjö K, Ceder L, Thorgren KG, Skytting B, Tidermark J, et al. Extramedullary fixation of 569 unstable intertrochanteric fractures: a randomized multicenter trial of the Medoff sliding plate versus three other screw-plate systems. *Acta Orthop Scand*. 2001 Apr;72(2):133-40.
5. Sahlatrand T. The Richard compression and sliding hip screw system in the treatment of intertrochanteric fractures. *Acta Orthop Scand*. 1974; 5:213-9.
6. Vishwanathan K, Akbari K, Patel AJ. Is the modified Harris hip score a valid and responsive instrument for outcome assessment in the Indian population with pertrochanteric fractures? *J Orthop*. 2018 Jan 3;15(1):40-46.
7. Saarenpää, T. Heikkinen, P. Jalovaara. Functional comparison of the dynamic hip screw and the Gamma locking nail in unstable trochanteric hip fractures: a matched-pair study of 268 patients *Int Orthop*. 2009;33(1):255-260.
8. George J. Haidukewych, T. Andrew Israel, Daniel J. Berry. Reverse Obliquity Fractures of the Intertrochanteric Region of the Femur. *The Journal of Bone Joint Surgery* 2001; 83(5):643-650.
9. SPS Gill, Ankit Mittal, Manish Raj, Pulkesh Singh, Sunil Kumar, Dinesh Kumar. Dynamic hip screw with locked plate VRS Proximal Femoral Nail for the management of intertrochanteric fracture: A comparative study *International Journal of Orthopaedics Sciences* 2017; 3(2): 173-180
10. Dahl E. Mortality and life expectancy after hip fractures. *Acta Orthop Scand*. 1980; 51:163.
11. Carlo Bellabarba, Dolfi Herscovici Jr., William M. Ricci. Percutaneous treatment of peritrochanteric fractures using the gamma nail. *Journal of Orthopaedic Trauma*. 2003;17(8 Suppl): S38-S50.
12. AK Rudramuni, Wadiraj Kulkar Study of surgical management of unstable trochanteric fractures using trochanteric supporting/stabilization locking compression plate *International Journal of Orthopaedics Sciences* 2022; 8(1): 543-546.
13. Khaleel, H. Morgagni's diaphragmatic hernia with Large ASD SECONDUM AND SEVER PHT mimicking a severe congenital heart disease in a newborn and cause delayed diagnosis of Morgagni's diaphragmatic hernia . a case report *Journal of Medical Research and Health Sciences*, 2022;5(3), 1832-1837.
14. Singh Arun, Thong G, Laloo N, Singh SN. Management of trochanteric fractures. *Indian Journal of Orthopaedics* 2023. 40